



**Ciprian OBER**, Phd, Associate Professor, Resident of  
European College of Veterinary Surgeons  
Department of Surgery  
Faculty of Veterinary Medicine Cluj-Napoca  
Phone: 0040749262180  
Email: ciprian.ober@usamvcluj.ro

**Owner:**

**Patient:** Mixed large breed dog, castrated female

**Surgeon:** Ciprian OBER, DVM, PhD, ResECVS

**Anamnesis:** found on the street

**Physical exam:** grade 3 lameness on right thoracic limb; limited range of motion at manipulation of right elbow joint

Limited range of motion at manipulation of both hips

**Complementary exams: X Rays**

**X rays:** *severe osteoarthritis of right elbow joint with the presence of a metallic wire probably from a previous attempt of a surgical repair*  
*Hip dysplasia*

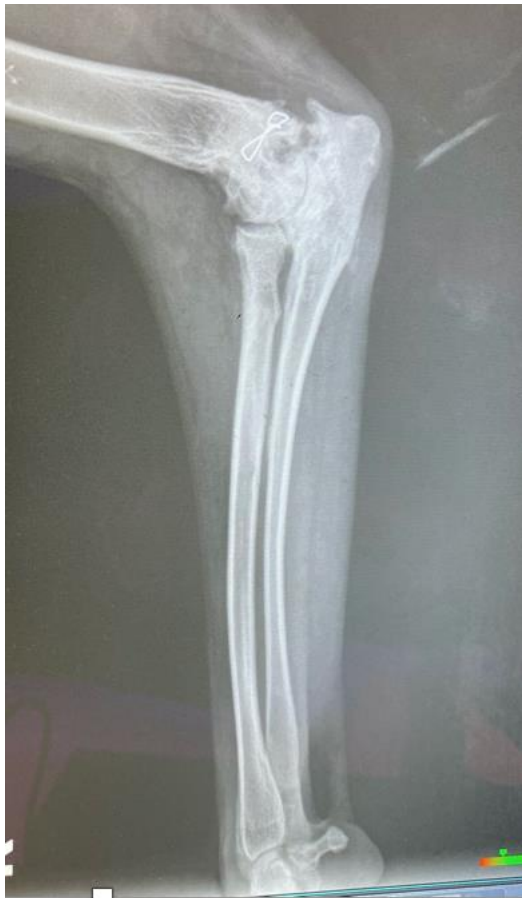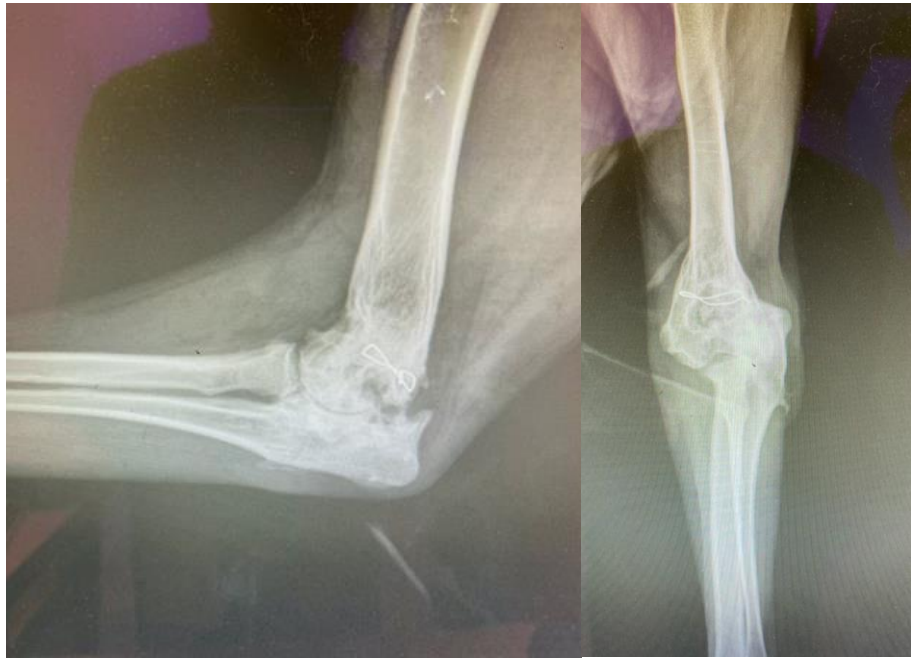
**Alternatives:**

**Right elbow joint:** *1. GOLD STANDARD: removal of the metallic wire and total elbow prosthesis (expensive procedure; only in few places in Europe and USA)*

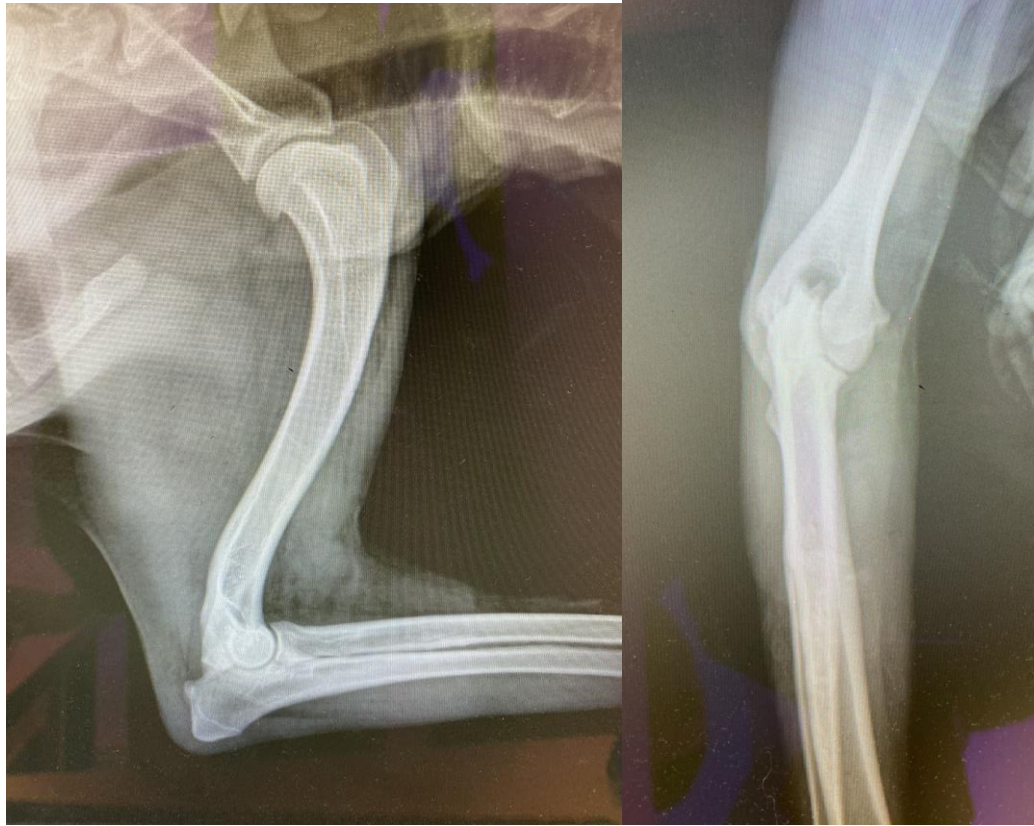
*2. Conservative management: maintenance of the normal weight; pain-killers, chondroprotective agents, limitation of heavy exercises*

*3. Arthrodesis of the elbow (Arthrodesis of the elbow is an alternative to amputation for severely comminuted intraarticular fractures, chronic luxation or subluxation from a variety of causes, and severe osteoarthritis. Elbow arthrodesis, however, produces a dramatic gait abnormality and should be considered only if the owner refuses amputation or if other limbs also have diseased joints. Some feel that amputation provides a better overall function than arthrodesis particularly if other joints are relatively pain free. Multiple-screw or bone plate fixation has yielded the best results in our experience.*

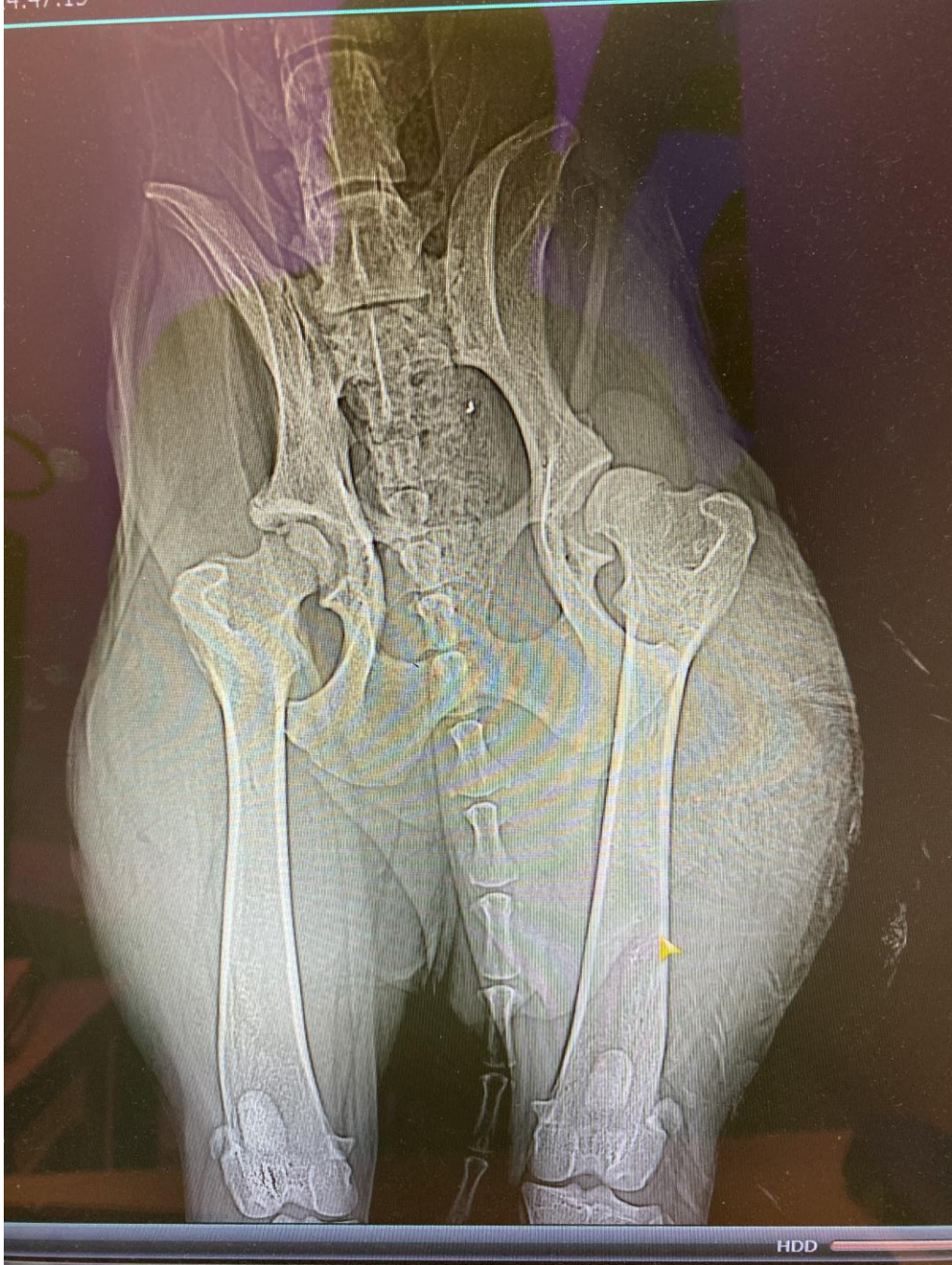
**Because of the concurrently hip dysplasia, this is not a viable solution.**



*Right elbow*



Normal left elbow



Hips