



UNIVERSITATEA DE ȘTIINȚE AGRICOLE ȘI MEDICINĂ VETERINARĂ DIN CLUJ-NAPOCA

Facultatea de Medicină Veterinară

Calea Mănăstur 3-5, 400372, Cluj-Napoca

Tel: 0264-596.384, Fax: 0264-593.792

www.usamvcluj.ro



Ciprian OBER, DVM, PhD, Conf.

Department of Surgery

Faculty of Veterinary Medicine Cluj-Napoca

Email: ciprian.ober@usamvcluj.ro

Owner: Lia Tarța

Patient: Mixed breed medium sized castrated adult dog (about 8 years old)

History: chronic lameness at right forelimb

Physical examination: moderate reduced range of motion of right elbow joint; right carpal joint ankylosis

Imagistic: *orthogonal radiographs*

Diagnosis: chronic right elbow subluxation with moderate to severe osteoarthritis

Ankylosis of the right carpal joint

Recommendations:

Librella sc monthly (see what's up)

OR

Previcox 227 mg (10 days with 14 days breaks - hepatic and kidney functions checked every 6 months)

Fish oil every day

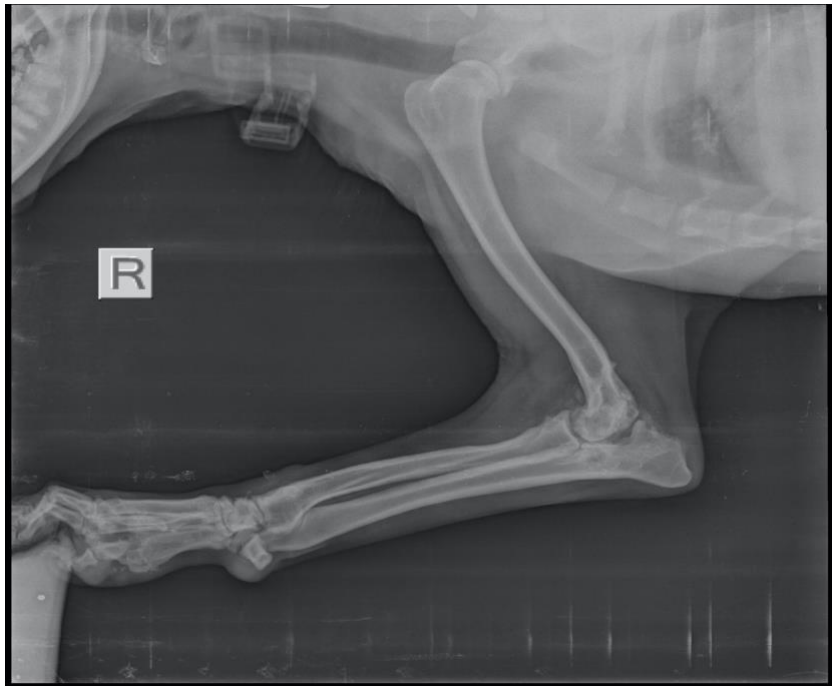
Weight management

Controlled exercises and activities

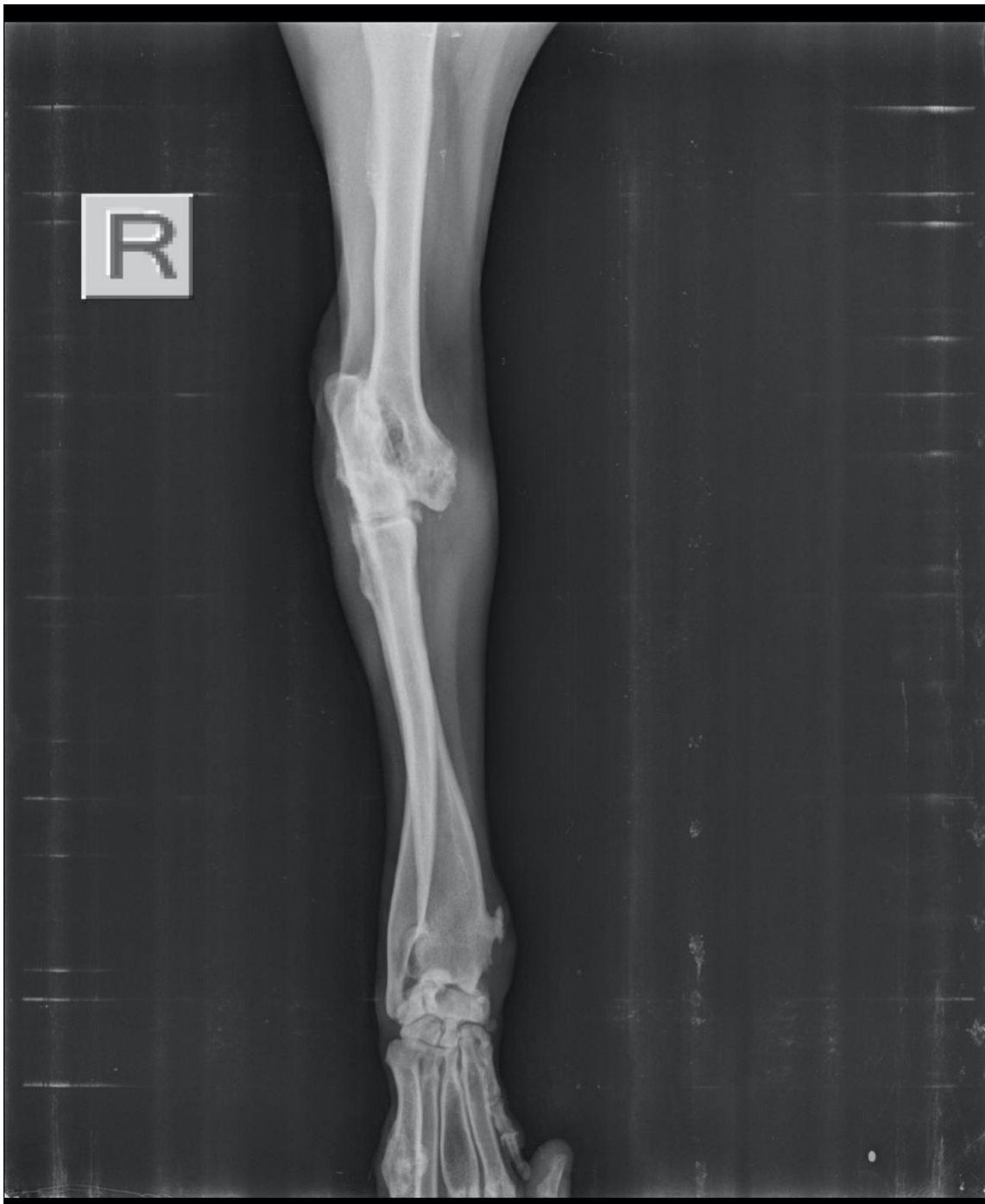Orthoses to protect the leg from injuries (see what's up)

If conservative treatment fails (OA process continues)

surgical alternatives are: total elbow replacement/elbow and carpal joint arthrodesis/amputation



**chronic right elbow subluxation with moderate to severe
osteoarthritis**



**chronic right elbow subluxation with moderate to severe
osteoarthritis**